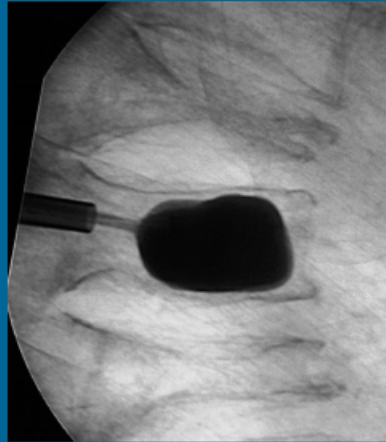
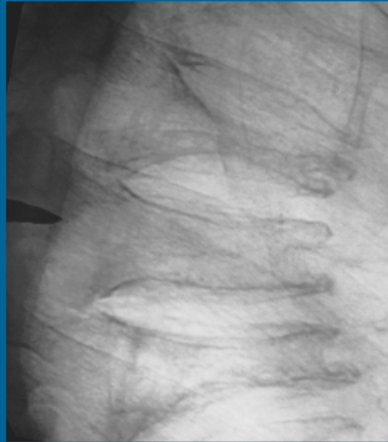


Patient: 80 Y, Male
Diagnosis: Osteoporosis
Fracture position: T-8



Kinetic

Kinetic

Kyphoplasty(PKP) case example

